

Localisation and characterisation of focal liver lesions using contrast-enhanced ultrasonographic visual cues

Spyridon Bakas¹

s.bakas@kingston.ac.uk

Katerina Chatzimichail²

katerina@hcsf.com

Awen Autret³

autretawen@gmail.com

Andreas Hoppe¹

a.hoppe@kingston.ac.uk

Vasileios Galariotis²

vgalariotis@hotmail.com

Dimitrios Makris¹

d.makris@kingston.ac.uk

¹ Digital Imaging Research Centre,

Kingston University,

Penrhyn Road,

Kingston upon Thames, Surrey,

KT1 2EE, London, U.K.

² University of Athens,

Radiology & Imaging Research Center,

Evgenidion University Hospital,

Papadiamantopoulou str. 20,

T.K.115 28, Athens, Greece.

³ Ecole Nationale Supérieure de

physique de Strasbourg,

Université de Strasbourg.

Abstract

Contrast-Enhanced Ultrasonography (CEUS) is a technique that has already gained acceptance in the detection and characterisation of very small focal liver lesions (FLLs). However, few radiologists and clinicians have been trained to perform CEUS and interpret its visual cues for diagnosis of FLLs. Based on the rising need to implement a certification tool for all radiologists, this paper describes an image processing approach to assist this routinely performed manual image interpretation task. The aim is to provide an efficient, informative and non-invasive evaluation tool that optimises the localisation and characterisation of small homogeneous hyper-enhancement category FLLs. Lowe's SIFT (Scale Invariant Feature Transform) keypoints are used to track the FLL region, when appearance is dramatically changed due to the effect of contrast agents. Generalised Procrustes Analysis estimates the FLL mean shape that is used for characterising each case as either benign or malignant. Our method characterised successfully focal liver lesions in all ten subjects under identical physical conditions.

1 Introduction

Hepatic disease, according to the British Liver Trust, has a continuously increasing impact and is currently the fifth largest cause of death in the UK. The group of hepatic disease is described by a number of medical conditions affecting the liver, e.g. hepatitis, cirrhosis, hepatocellular carcinoma (HCC), etc. These conditions are either harmless conditions (benignities), or progressively worsening diseases that potentially result in death (malignancies).

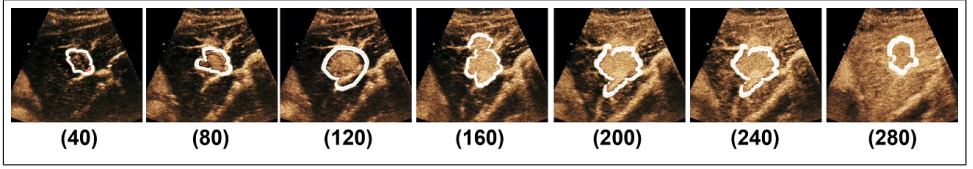


Figure 1: Focal liver lesion (FLL) tracking in the arterial phase, where the appearance of the liver changes significantly. The third image (frame 120) is the frame where the FLL is initialised.

HCC, which is the fifth most common cancer [5], is characterised as a malignant focal liver lesion (FLL). FLLs are solid or liquid-containing nodules, "foreign" to the liver's anatomy. Extreme interest attracts the ability to distinguish any case of premature (small) malignant FLL from a benign, as it can be healed without performing any surgical operation.

Visualisation of possible lesions has been attempted by employing different diagnostic imaging techniques throughout the years. Ultrasonography (US) has limited sensitivity in the small masses' detection and provide vague results when compared to Computed Tomography (CT) and Magnetic Resonance Imaging (MRI). CT and MRI were used to clarify the US results and evaluate a lesion's existence. Recently, contrast-enhanced (CE) US has gained acceptance in the detection and characterisation of very small FLLs [6, 7] and is supported as the reliable replacement of CT and MRI in the characterisation of HCC [8]. CEUS is based on the intravenous injection of microbubble contrast agents, first introduced in the late '90s, and offers a display enhancement in gray-scale, by maximising the contrast between the FLL and the rest of the liver (parenchyma). However, few radiologists have been trained to perform CEUS and interpret its visual cues for diagnosis of FLLs.

There is a rising need to use CEUS and create a software tool for clinicians and radiologists, mainly for two reasons; a) its relatively inexpensive and portable technology, when compared to other techniques (e.g. CT, MRI) and b) its effectiveness in the FLLs' evaluation that exceeds the 90%, according to radiologists. This paper describes a methodology to track FLLs over time and characterise them to, either benign or malignant cases. More specifically, we propose tracking over time the FLLs using Lowe's scale-invariant keypoints detector (SIFT) [9] to overcome the dramatic appearance changes during a CEUS examination [Figure 1]. The area and shape descriptors, derived by tracking, are combined with the Generalised Procrustes Analysis (GPA) [10] to localise the FLL at the end of the examination and characterise it as either benign or malignant.

2 Methodology

The examination of CEUS includes three phases, whose durations vary, mainly depending on the pathology of the patient's liver and heart. After the second generation contrast agents' intravenous injection, the change of brightness intensity with respect to the elapsed time, represents the vitality of a FLL, by screening the inflow and outflow of the agent itself. The phases are named after considering the fact that the liver is supplied with blood first from the hepatic artery and then by the portal vein. The first phase of CEUS, (arterial phase or enrichment) happens when contrast agents enrich (make brighter) the area of the liver. Homogeneous hyper-enhancement category FLLs, independent of their kind (benign/malignant), are enriched prior to the parenchyma. During the second phase (portal venous phase), the




Figure 2: a) Labeling of the liver’s area on the late phase, in a malignant FLL’s case. b) Areas segmented after the automatic threshold application. c) Shape information localising a FLL in the late phase.

concentration and flow of contrast agents are stabilised. Then, the third phase (late phase, acidic or parenchymatic) is characterised by the outflow of the agents from the lesion and the parenchyma. It is mainly on the third phase where the FLL’s category is identified [24]. In their overwhelming majority, if the FLL is benign, it stays enriched for longer compared to the parenchyma. On the contrary, if the FLL is malignant, the contrast agents outflow the lesion prior to the parenchyma.

The video sequence of the arterial phase is processed, to obtain the area and shape descriptors of the FLL. Initially, the conical area covered by the US is selected and after removing any artefacts, is set as the mask of our workspace (US mask). The artefacts refer to regions that their brightness intensity has been enhanced prior to the examination, by the radiologist adjusting the controls of the US scanner. The FLL mask is manually initialised on a single frame, ideally the one with the maximum contrast between FLL and parenchyma [Figure 1].

The FLL mask is tracked backward and forward in time from the frame it is initialised [Figure 1]. A histogram of the FLL mask of the previous frame is used to specify a threshold to separate the lesion from the parenchyma in the current frame. The thresholded image is cleaned using morphological opening with a disk-shaped structuring element of 5-pixels diameter. Subsequently, the resulted image is segmented using the connected components algorithm. If the segmentation result is consistent to the FLL region of the previous frame, then it is set as the new FLL region. This consistency is verified by two conditions: a) the relative size difference of the FLL regions between the two frames being less than D_s (e.g. $D_s = 30\%$) and b) the displacement of the FLL’s centre of gravity (CoG) between the two frames being smaller than D_d (e.g. $D_d = 10$ pixels). However, the resulted FLL region may not be consistent to the previous frame, either because of the appearance change of the lesion and the parenchyma or because of the movement of the transducer. In that case, we use SIFT keypoints [25] detected in the previous frame and match them with SIFT keypoints in the current frame. The current FLL region will then be given by the FLL region of the previous frame, translated by the average displacement of the SIFT keypoints. The derived contours extracted from tracking the FLL region in all frames of the arterial phase video sequence are aligned and their mean shape is estimated using GPA [26].

An image from the late phase is then used to characterise the FLL as either benign or malignant. First, the liver area is manually specified on the image [Figure 2(a)] and its intersection with the US mask defines the region of interest (ROI). The ROI is smoothed by a gaussian filter and then its histogram is computed. Subsequently, a threshold is automatically selected based on Otsu’s method [27] in order to binarise the ROI into foreground and background. The morphological operators of opening and closing are applied to the foreground

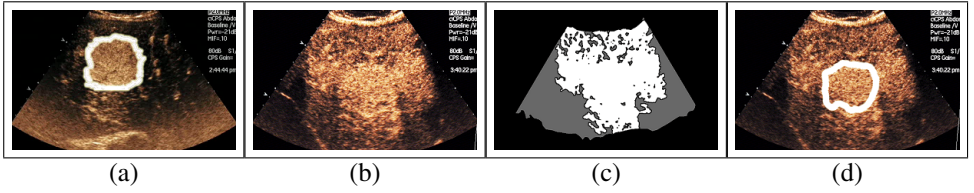


Figure 3: Case study depicting a cirrhotic liver with a malignant lesion. a) Initialisation of the hyper-enhancement category FLL during the arterial phase. b) Static image of the late phase. c) FLL localisation by using input only from the late phase (baseline method). White area depicts the FLL and gray area the parenchyma. d) FLL localisation by our method.

and background areas respectively to remove small regions (noise), protrusions from objects and thin connections between objects. The ROI is segmented using connected components and removal of the small areas. The FLL area is localised by maximising the intersection between the segmented areas [Figure 2(b)] and the mean shape found in the arterial phase, allowing translation and rotation of the latter [Figure 2(c)]. Characterisation of a FLL is based on the sign of the difference between the average intensity of the FLL and the parenchyma, within the ROI.

3 Experiments & Results

The Ultrasonographic equipment used for the data acquisition was a Siemens ACUSON Sequoia C512 system, in combination with low-frequency 6C2 convex Transducer (2-6 MHz) at 25 frames-per-second. The second generation contrast media used is sulphur hexafluoride gas (SonoVue from Bracco Diagnostics). Acquisition parameters were set by the radiologist, separately for each patient. The captured data were exported as video sequences and images of 768 x 576 pixels, with no compression applied.

The visual cues used are clinical data of ten patients with identical physical condition. Each case is described by one short video sequence of the arterial phase and one static image of the late phase, where we assume that only one homogeneous hyper-enhancement category FLL exists within the liver of each patient, with diameter between 0.5 and 6 cm. Motion artefacts, acoustic shadows and US absorption inevitably degraded the quality of our imagery. Moreover, transducer movement and the patient's fragile breathing patterns also have an effect on the quality of our recordings. In four out of ten cases, the FLL was not continuously observed because of either out-of-plane lesion movement or its dispersion in depth.

To demonstrate the effectiveness of the different parts of our methodology, we compare it with a simplified baseline version, where only the image from the late phase is used, based on the fact that a FLL may be characterised by using input only from the late phase. The liver area is smoothed and then thresholded into foreground (bright) and background (darker) populations, in the same way as we described in our methodology. Very small areas are removed, after the connected component areas have been labeled. If the foreground population is larger than the background population, the foreground area is labelled to be parenchyma, as a FLL cannot cover an area larger than the parenchyma, and the FLL is therefore characterised as malignant. Otherwise, the foreground area is labelled as FLL, which is characterised as benign. The success rate of this characterisation method, despite its simple nature, is 80% when compared to the gold standard.

Case Studies	1	2	3	4	5	6	7	8	9	10
Gold Standard	M	B	M	M	M	B	M	M	B	M
Baseline Method	M	M	M	M	M	B	M	B	B	M
Our Method	M	B	M	M	M	B	M	M	B	M

Figure 4: Results of baseline and proposed method. (B::Benign , M::Malignant)

Finally, our methodology, as described in section 2, achieves 100% characterisation rate [Figure 4]. This is achieved because it explicitly estimates the FLL’s size and shape from the arterial phase, which allow an accurate localisation of the FLL in the late phase.

The most interesting of our case studies [Figure 4 (case study 8)] included a cirrhotic liver with a malignant lesion [Figure 3], depicting both the parenchyma and the FLL brighter than the surrounding area in the late phase [Figure 3(b)]. The baseline method assumed almost all the liver as a big FLL and the surrounding areas as the parenchyma, characterising the FLL as benign [Figure 3(c)]. Our method used information of FLL’s size and shape to localise it precisely [Figure 3(d)] and then by a temporal averaging of the brightness intensities of the FLL and the parenchyma, it found that the former was darker than the latter and characterised the case correctly.

4 Conclusions & Future Work

This paper presented a methodology for localising homogeneous hyper-enhancement category FLLs over time and characterising them as either benign or malignant. Experimental results on ten case studies of different patients with identical physical condition demonstrate 100% success rate. Tracking the FLL area in the arterial phase using SIFT keypoints and estimating its mean size and shape using the GPA are essential for the success of our approach.

Our methodology requires the manual definition of the US area on the first frame, the FLL area on a single frame of the arterial phase and the liver area on the late phase image. Automatic localisation of the above areas would allow a fully automatic method. We plan to extend our methodology to heterogenous hyper-enhancement category FLLs, as well as to heterogeneous hypo-enhancement category FLLs. Future work also includes investigation of cases of undetectable damage and cases with more than one FLL within the liver, as well as the ability to distinguish between the different types of benign and malignant FLLs [8].

References

[1] D.G.Lowe. Distinctive image features from scale-invariant keypoints. *International Journal of Computer Vision*, 60(2):91–110, 2004.

[2] J.Bruix, G.Gores, and M.Kojiro. Monothematic conference: Hepatocellular carcinoma - towards molecular profiling of clinical management. *EASL - AASLD - JSH*, June 2005.

[3] J.Gower. Generalized procrustes analysis. *Psychometrika*, 40:33–51, 1975.

[4] J.M.Llovet. Updated treatment approach to hepatocellular carcinoma. *Journal of Gastroenterology*, 40:225–235, 2005.

- [5] J.M.Llovet, A.Burroughs, and J.Bruix. Hepatocellular carcinoma. *Lancet*, 362:1907–1917, 2003.
- [6] N.Otsu. A threshold selection method from gray-level histograms. *IEEE Transactions on Systems, Man, and Cybernetics*, 9(1):62–66, 1979.
- [7] R.S.Goertz, T.Bernatik, D.Strobel, E.G.Hahn, and T.Haendl. Software-based quantification of contrast-enhanced ultrasound in focal liver lesions - a feasibility study. *European Journal of Radiology*, 75:22–26, 2010.
- [8] S.R.Wilson and P.N.Burns. Microbubble-enhanced us in body imaging: what role? *Radiology*, 257(1):24–39, Oct. 2010.